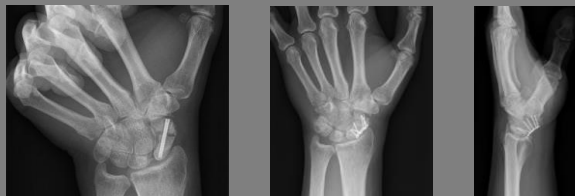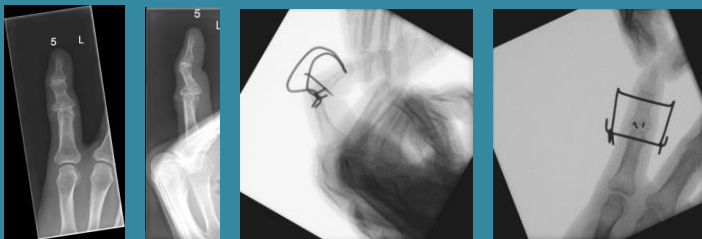


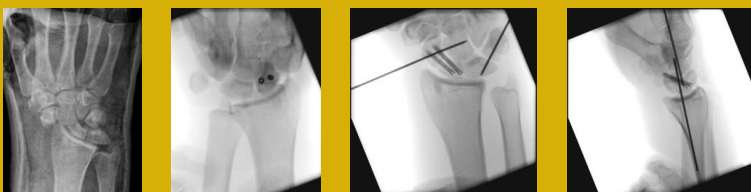
Scaphoid non-union after screw fixation is treated with iliac crest bone graft and new synthesis with a plate.




PIP joint pilon fracture is treated with a modified Suzuki frame and immediate protected mobilization.



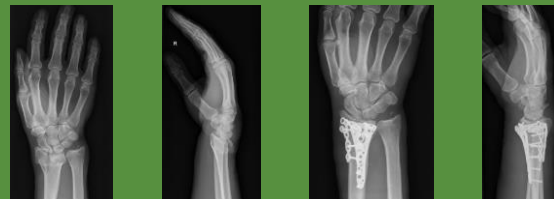Greater-arc perilunate dislocation: scaphoid fracture is treated with dorsal approach and double screw technique, distal scaphoid and lunate are temporarily fixed with 2 K-wires.



The FESSH Travel Award has been a great opportunity to visit a new and modern Hand Surgery Department in which I got the chance to learn and appreciate hand traumatology at its finest. This fellowship has been an excellent way to study advanced surgical techniques but also the starting point to create new bonds for mutual enrichment and exchanges in the future. I met surgeons with outstanding traumatological skills in the theatre and, at the same time, good friends outside the hospital. Thanks to FESSH, Tirol Kliniken, Prof. R. Arora (Klinikdirektor), PD G. Schmidle (Teamleiter) and the whole Hand Trauma Team.



AO C3 radius fracture is reduced and fixed with combined dorsal and volar plating, arthroscopically assisted.




CONFIRMATION
for
Dr. Filippo Pantaleoni

This is to confirm that Dr. Filippo Pantaleoni completed a fellowship from August 2nd till 20th 2021 under the supervision of Univ.-Prof. Dr. Rohit Arora at the Department of Orthopaedics and Traumatology at Medical University Innsbruck, Austria.

During his stay Dr. Pantaleoni was well integrated in our hand team and could accompany them in the daily routine. He was involved in the morning and afternoon sessions, and was an active part in several case discussions; furthermore he participated actively in consultations of clinic hosted patients and in outpatient's clinic.

We appreciated the exchange of expert knowledge and wish him all the best and hope to keep in friendly touch also outside the fellowship!



Univ.-Prof. Dr. Rohit Arora
(Head of Department)