Federation of European Societies for Surgery of the Hand - Travel Award.
Awarded to Mr John K. Dickson, to provide sponsorship for a fellowship at: -

The Hand Clinic

Windsor, England

Established in 1989, the Windsor Hand Clinic is a private, independent, surgical unit specialising in Hand Surgery. The clinic was designed as a compact day surgery unit including operating and X-ray facilities, rehabilitation and consulting rooms. All surgery is conducted under local or regional anaesthesia. There are no inpatient beds.

Operating Theatre at The Hand Clinic

From left to right : Donald Sammut; David Evans; John Dickson

Consultants: Mr David M. Evans; Mr Donald Sammut; Mr David L. Martin; Mr Henk Giele; Miss Alice T. Bremner-Smith.

FESSH Travel Award
Trainee Fellowship: February 2011 - April 2011
Undertaken by: Mr John K. Dickson (MBBChir MA Cantab MRCS)

Instruction and teaching was provided in the operating theatre and in the clinic. Opportunities to contribute to scientific research were also provided leading to presentation and publication.

Novel and innovative methods and techniques were demonstrated. In particular, the "Open Skies" technique for repairing a divided flexor tendon. This method, which has been developed by Mr Donald Sammut, involves dividing the pulleys to allow for easy access when repairing divided flexor tendons. Following repair of the tendon the pulley is repaired to prevent bowstringing.

The Hand Clinic, Oakley Green, Windsor, SL4 4LH, England.
Tel: 01753 831333. Fax: 01753 832109. Email: mail@hand-clinic.co.uk

Reconstruction of the Radial Collateral Ligament of the Metacarpophalangeal Joint of the Fingers

Complete rupture of the radial collateral ligament of the metacarpophalangeal joint of the third and fourth fingers is uncommon (figure 1A). As the ligament is inaccessible for direct repair, it is best reconstructed using a tendon graft, resulting in improved function and eliminating pain. In 1979, Zancolli described the Assemblage Nucleus, an agglomeration of fibrous structures through which the soft tissues in the palm are held in the concavity of the transverse palmar arch (figure 1B). If the collateral ligament is lax or ruptured, then the assemblage nucleus will no longer be suspended, leading to changes in the mechanics of flexion and of the MP joint itself (figure 1C). The illustrated operative technique (developed by Mr David Evans) requires both a dorsal and volar incision. A drill hole is made through the metacarpal head at a point corresponding to the proximal attachment of the collateral ligament (figure 1D). The 2 ends of a tendon graft are delivered through 2 holes in the deep transverse metacarpal ligament at a point just adjacent to the assemblage nucleus. One end is passed through the hole in the metacarpal head and a stab incision made through it (figure 1E). The other tendon end can then be delivered through this stab incision and pulled tight, so as to relocate the assemblage nucleus and create a strong repair (figure 1F).

In our case series of 8 patients, the average post operative Quick DASH score was 1.9. All patients were able to return to work and 7 of the 8 patients reported being completely pain free.

Figure 1: Rupture to the Collateral Lig of the MCPJ - Reconstructive Technique

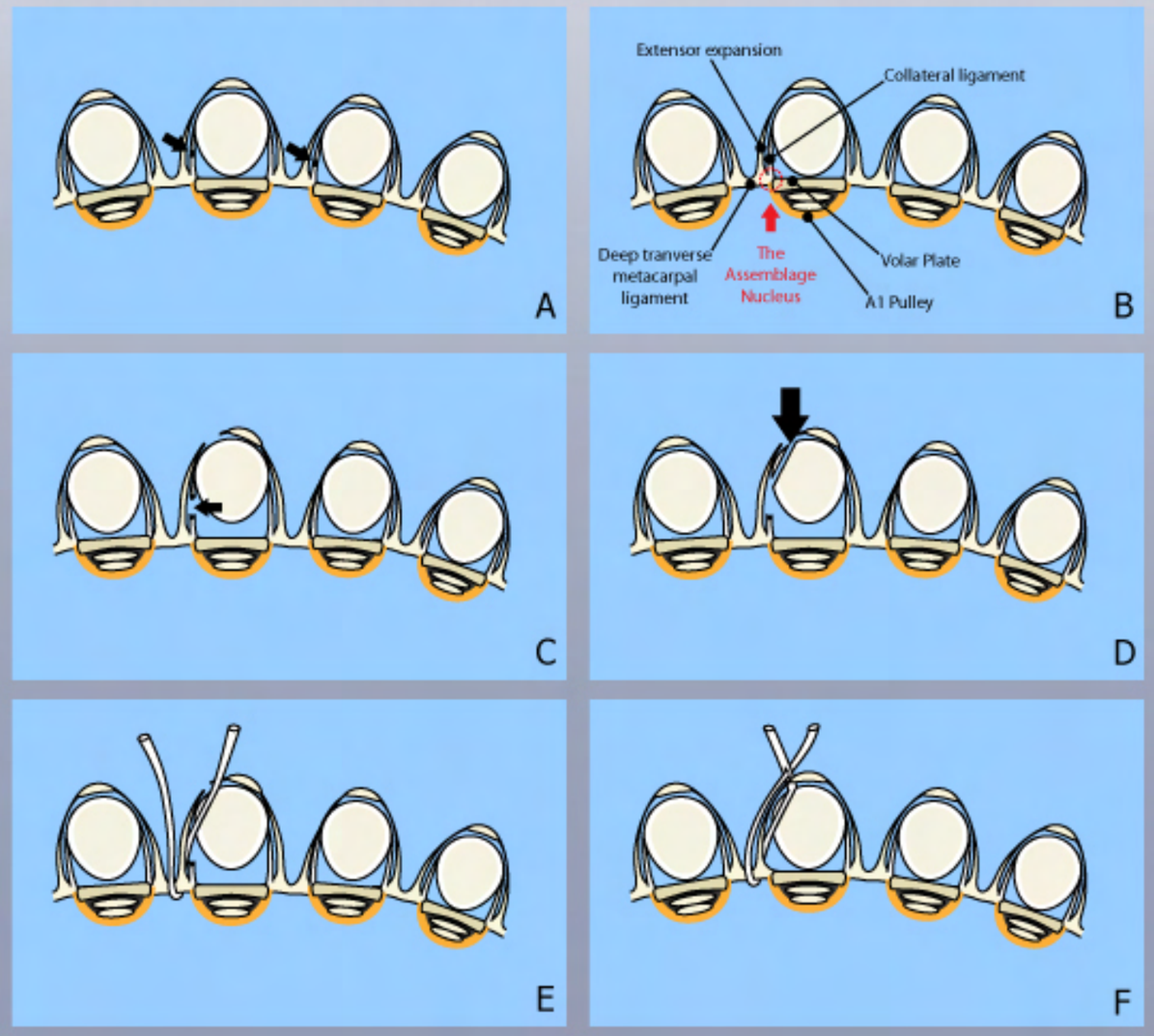

A - Rupture of the Radial Collateral ligament of the MCPJ of the 3rd or 4th fingers
B - The Assemblage Nucleus
C - When the collateral ligament is ruptured the assemblage nucleus is no longer suspended
D - A drill hole is made through the metacarpal head
E - The 2 ends of a tendon graft are delivered through 2 holes in the deep transverse metacarpal ligament. One end is passed through the hole in the metacarpal head and a stab incision made through it.
F - The other tendon end can then be delivered through this stab incision and pulled tight, so as to relocate the assemblage nucleus and create a strong repair.